

## Tibial Plateau Levelling Osteotomy by Radial Cut

Tibial Plateau Levelling Osteotomy (TPLO) is an increasingly popular method for treatment of canine cranial cruciate ligament disease. This article covers indications for the procedure and provides an overview of Radial Cut TPLO surgery.

### Indications:

TPLO may be used to treat cranial cruciate ligament disease in all sizes of dog. The choice of surgical technique is multifactorial, and will take into account available equipment, expertise and economic factors together with biological and biomechanical considerations. Those particularly pertinent to TPLO include:

#### Bodyweight:

TPLO is most frequently performed in medium to giant breeds. Greater bodyweight is a positive indicator for selection of TPLO as a treatment option.

#### Size:

Also a consideration, with long-limbed, rangey dogs (eg. lurchers, border collies) benefiting from TPLO surgery although being of relatively light bodyweight. The author would typically consider TPLO surgery for breed sizes from Staffordshire Bull Terriers and Springer Spaniels upwards, whilst typically employing a lateral fabella suture technique for smaller breeds (with some exceptions, see below).

#### Age:

Cruciate ligament degeneration is seen increasingly in young large breeds, in some cases within their first year. Minimising osteoarthritis in the long term is a priority for these young dogs. Many surgeons believe that this leads to the TPLO being the technique of choice, although long term comparative studies continue to investigate this. These cases frequently show bilateral degeneration, and partial cruciate ruptures are common. The author restricts the procedure to dogs over 6 months of age, with progression of ossification of proximal tibial growth plates.

#### Partial ligament rupture.

Cases of partial ligament rupture show a very rapid improvement following TPLO. Importantly, they typically do not progress to complete ligament failure as TPLO acts to neutralise the forces on the cranial cruciate ligament.

#### Performance.

TPLO is widely accepted to give the best functional outcome, in the short to medium term, and has enabled working/performance animals to return to high functional standards.

#### Bilateral presentations:

The relatively rapid return to function makes TPLO a

popular choice for bilaterally affected dogs. Whilst bilateral surgery is described, the author prefers at least a 3 week interval between operations.

#### Excessively sloping tibial plateau:

Average plateau angles range from 22°-26°, and in the authors experience can range as low as 15° and still remain a TPLO candidate with good post-operative outcome. However, in cases with an increased tibial plateau angle, TPLO has proved particularly beneficial. Case studies have advocated TPLO as the technique of choice for even small breeds with excessive tibial plateau slopes. In some of those cases the amount of angular correction required leads to a Wedge resection technique being favoured over the Slocum(curved-cut) TPLO.

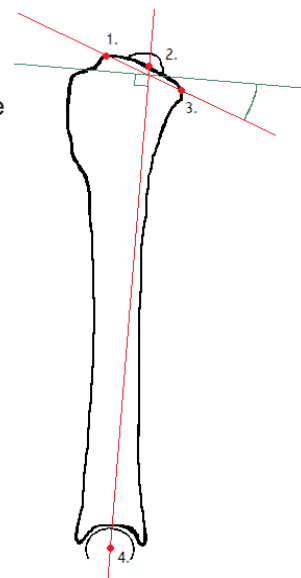
#### Cranially translocated tibial crest.

Occasionally the stifle will rest with the tibia cranially translocated following cruciate rupture the tibial crest is palpated cranially, the patella tendon is less distinct, and the first movement during cranial drawer is backwards, often associated with a dramatic degree of movement. In the author's experience these cases may return to cranial translocation with significant recurrence of lameness some weeks after extracapsular lateral fabella suture placement, but in a limited number of cases have shown better outcomes following TPLO.

### Technique:

#### Tibial Plateau Measurement:

The diagram illustrates the landmarks for measuring the tibial plateau angle. The entire stifle to hock area should be included on the radiograph, and a true lateral is required. Tibial plateau angles from 15° upwards are candidates for TPLO. Typical or 'normal' angles are breed variable and generally within the range 22°-26°. The 'target' post-operatively is 5°. Following measurement of the tibial plateau angle the required distance for rotation can be read from calculation tables for each of four different saw blade curvatures. Angular limb deformities may be appreciated from torsional abnormalities on radiographs, and in some cases can be treated within the TPLO procedure.

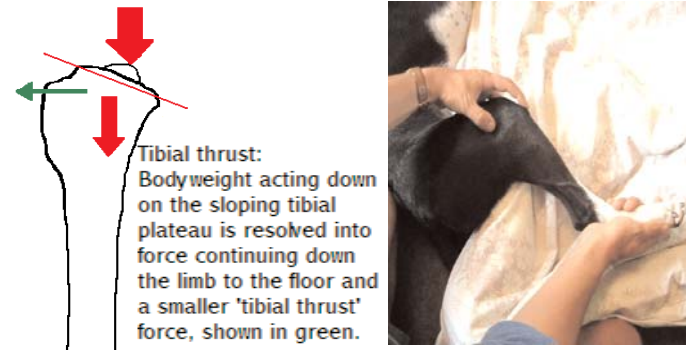


1. Cranial aspect tibial plateau
2. Base of intratrochanteric eminences
3. Caudal aspect tibial plateau
4. Centre of talus

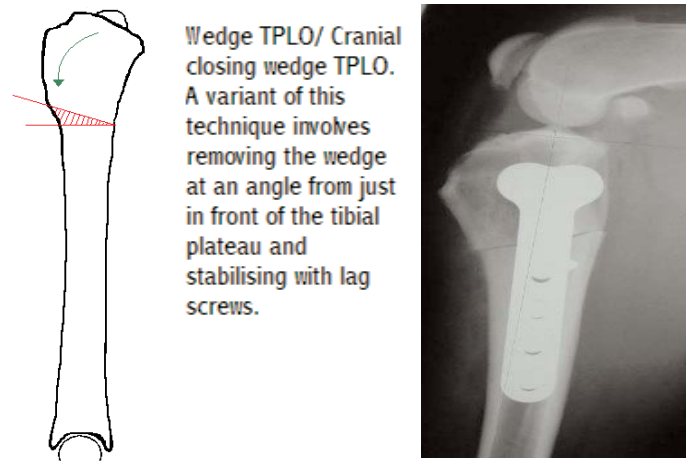
Landmarks for the measurement of tibial plateau angle

**Theoretical overview:**

Levelling the tibial plateau aims to eliminate the 'tibial thrust' force exerted during weightbearing. In effect, rather than replace the torn cruciate ligament it aims to convert the stifle so that a ligament is no longer required during weightbearing.



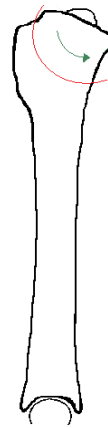
Tibial thrust. In the cruciate deficient stifle, as the joint is loaded by flexing the hock the resultant forces push the tibial crest cranially which is palpable. Altering the angle of the tibial plateau neutralises the tibial thrust.



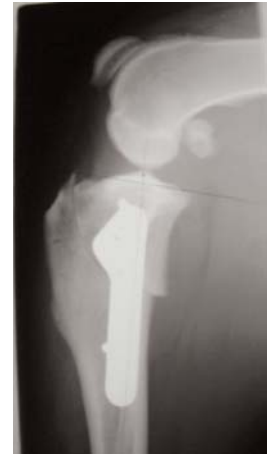Current techniques include Wedge TPLO. See above.

**Radial Cut TPLO.**

This is a refinement of the Wedge TPLO, but requires more extensive equipment and training. It was subject to a patent restricting its performance to those surgeons attending a Slocum course. Refinement and research of elements of the TPLO procedure is ongoing, particularly of the meniscal release, the biomechanics of the osteotomy and its stabilisation, and into the long term effects on osteoarthritis development. Arthroscopic examination of the stifle as the initial part of the procedure is becoming increasingly popular.



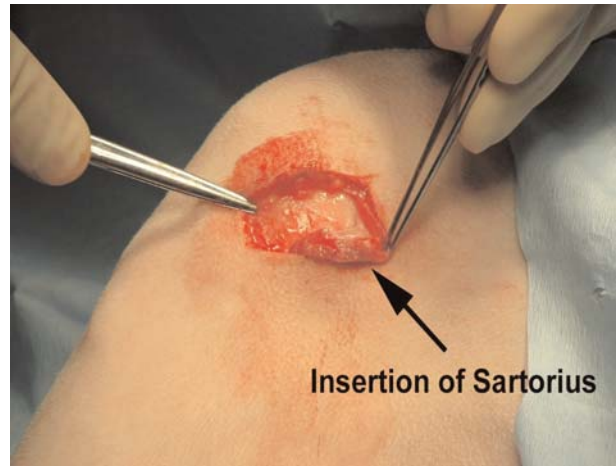**Slocum/ Curved cut TPLO.**  
Once rotated to the prescribed degree fixation is achieved with a heavily contoured compression plate. Curved osteotomy shown in red.



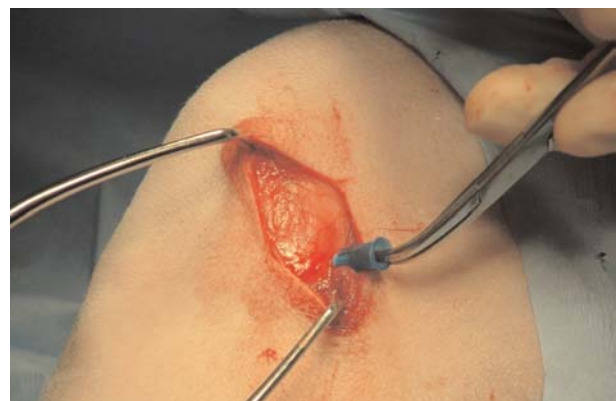**Surgical Preparation:**

Epidural and intra-articular analgesia are routinely administered, supporting opioid and non-steroidal parenteral analgesia. A hip-to-hock clip and hanging limb preparation precede four quadrant draping followed by fenestrated overdrape with the patient in lateral recumbency. The limb is free draped, typically with autoclaved self-adhering bandage. The patient is then moved to dorsal recumbency with the limb lying flat to the side, medial aspect uppermost.

**Surgical Procedure:**

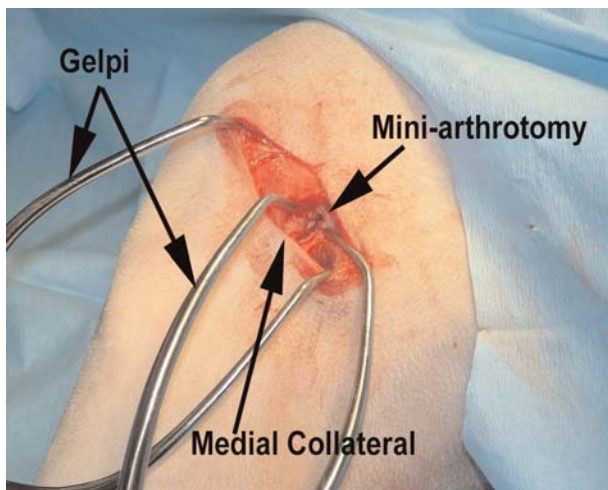


A caudomedial incision is made, centered over the stifle joint space. The Insertion of the sartorius is identified, freed cranially and retracted caudally. The medial collateral ligament is identified.



The joint space is located with 23g hypodermic needle. Extensive medial tibial buttress fibrosis may complicate this approach.





A mini-arthrotomy incision made caudal to medial collateral ligament, joint capsule retracted to show incised medial meniscus. Caudal partial meniscectomy and excision of bucket handle tears are typically possible through this approach if required. If meniscal damage is more extensive then a medial parapatellar approach may be made. Meniscal inspection, trimming and release as required may also be performed arthroscopically.

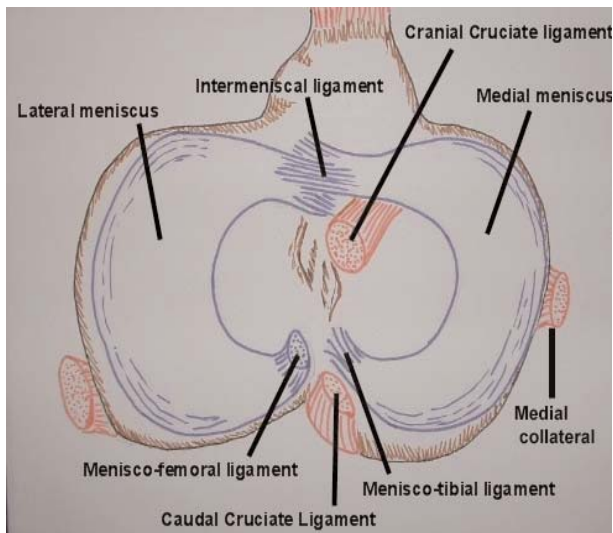


Diagram showing lateral, medial meniscus and related structures. Note non articular areas which are safe for the placement of stifle distractors and Hohmanns. Note also presence of menisco-femoral ligament on the lateral meniscus which limits damage to this structure as the lateral meniscus has to move with the femur, unlike the medial meniscus.

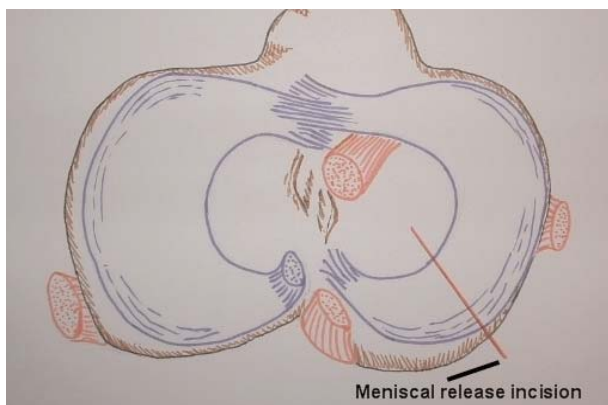
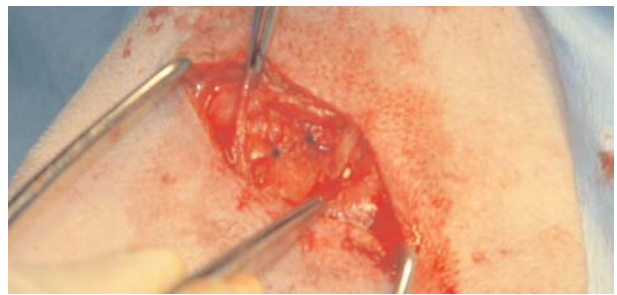
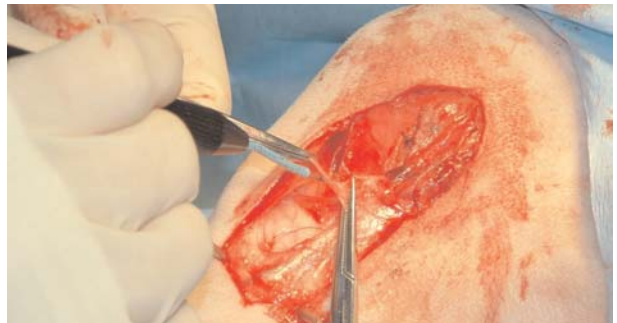

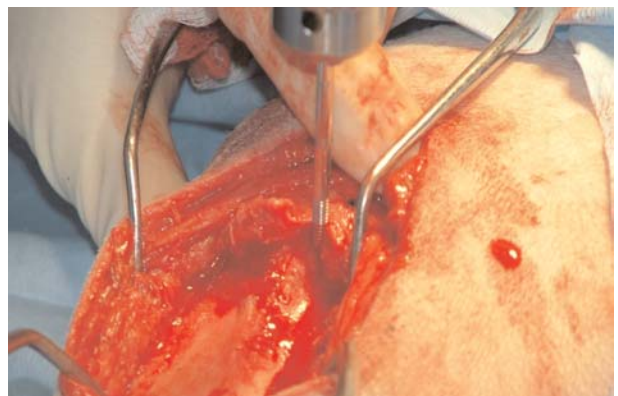Diagram indicating site of meniscal release incision. Where marked stifle instability is present meniscal release aims to prevent the caudal medial meniscus being trapped between the femur and the tibia and damaged during cranial tibial translocation at weightbearing. The assumption is made that no meniscus is better than a damaged one.



The joint capsule is closed. Care taken not to catch the severed meniscus (if release performed) in the suture and re-tether it.



Surgical incision is continued distally over proximal third of the tibia. Diathermy of small blood vessels traversing the osteotomy site is helpful. Periosteum is incised and retracted from the entirety of the medial and caudal tibia.

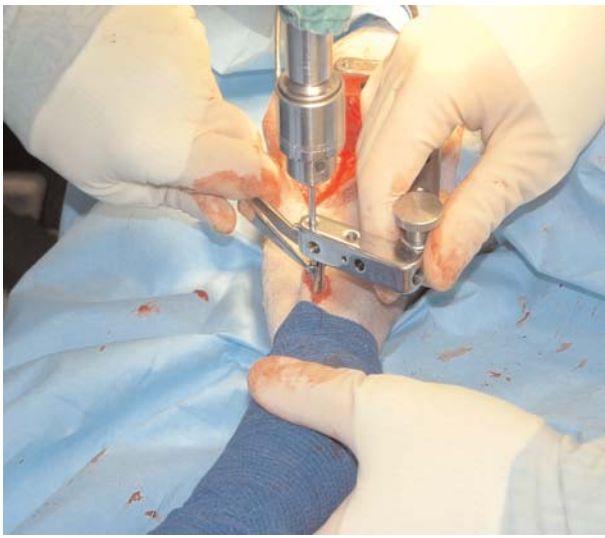

Placement of proximal jig pin. The proximal jig pin necessarily acts as the centre of rotation of the proximal portion. If a curved cut arc is not centred on the proximal jig pin by any margin, then the jig fixation will create gapping at the osteotomy as the proximal portion rotates. Studies have looked at the best site of the centre of rotation, with the caudal angle of the plateau being one option.

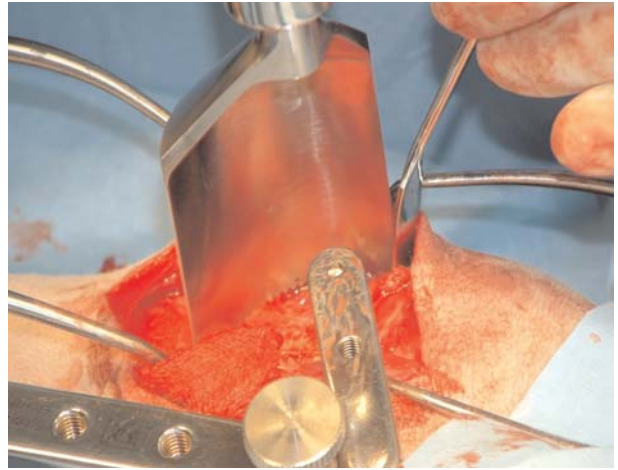
However, given that there is a certain range of saw blade diameters (most commonly 24mm and 30mm), and that siting of the osteotomy should ensure that you are left with as large a tibial crest remnant as possible, and avoid impinging on the cranial aspect of the tibial plateau, restricting the centering of the osteotomy to precisely the jig pin placed at the caudal tibial plateau angle is not always helpful. Work by Kowaleski suggests that for best results the osteotomy should be centered at the center of rotation of the joint which is rarely the proximal jig pin. The center has been described as being around the intercondylar eminence. Templates and guides designed by Cal Cadmus are available to help center the osteotomy.

Use of the fixation jig for initial procedures is certainly advised, as it can aid the perpendicular alignment of the osteotomy. With familiarity with the procedure, the benefits of the jig for osteotomy alignment become less and may be dispensed with.

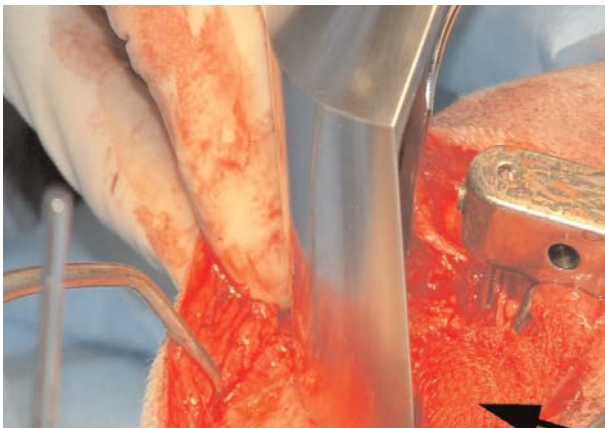



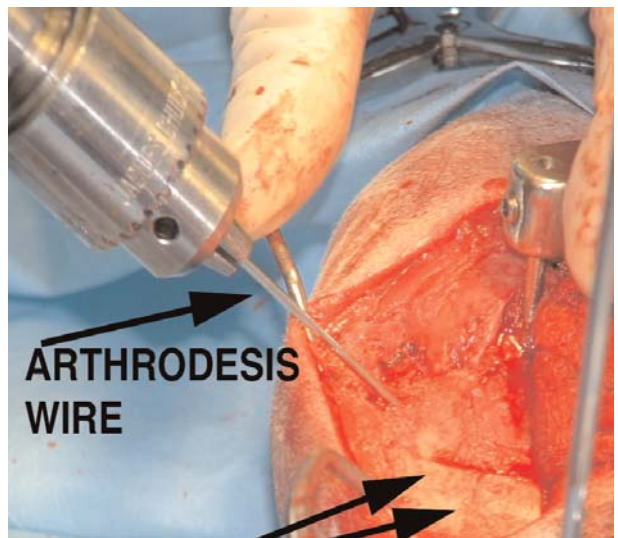
Placement of distal jig pin in distal one third of the tibia. The body of the jig sits caudal to the pins.



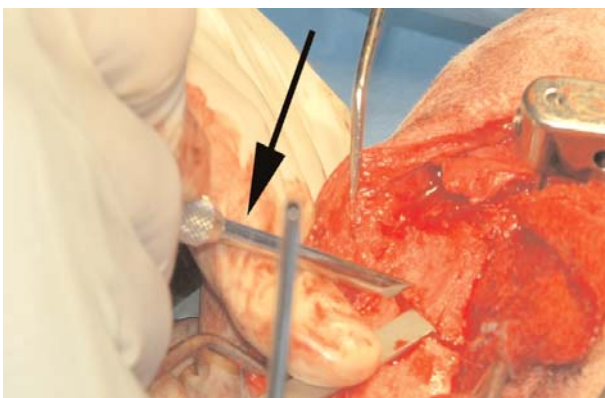
The cut is completed taking care to remove any bone spikes which would interfere with the smooth rotation of the proximal segment.



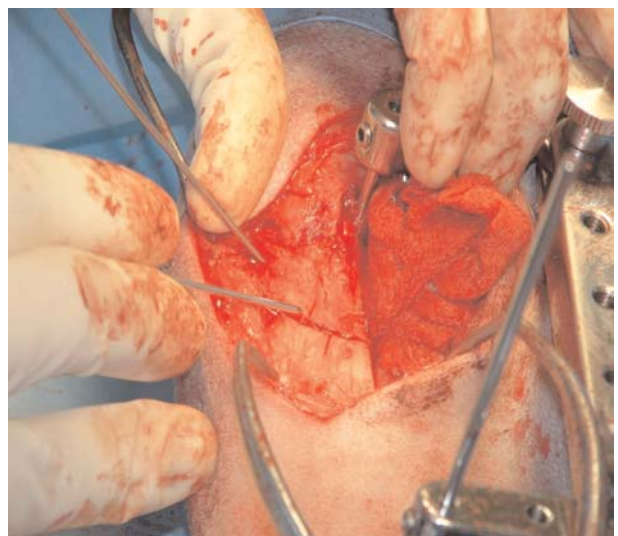
A swab placed at caudal tibial aspect protects the gastrocnemius muscle belly as the osteotomy is begun. The blade should be positioned to exit the caudal border of the tibia at right angles and to leave as much tibial crest intact as possible without compromising articular structures. The blade should enter the bone at right angles to the medial surface of the tibia. The angle and position of the blade should be checked and double checked before cutting. A radial or biradial blade is difficult to control so a firm grip is required to prevent saw blade 'skate'. Lubrication of the saw blade is essential to decrease thermal necrosis at the site. Always use a sharp blade. Some saw blades will also require regular sharpening, others are semi disposable.



After completion of osteotomy an angled pin (arthrodesis wire) is placed to enable rotation of proximal tibia. Using a mini-driver rather than a drill chuck speeds up this part of the procedure.

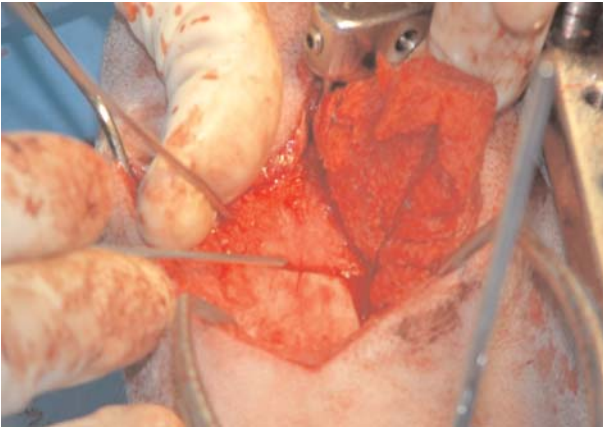


The amount of rotation required is calculated using the tables provided with each saw blade. The correction will be achieved by rotating the proximal segment a certain distance. (between 5mm and 15mm). With the osteotomy only partially completed, the distance for rotation is marked using a set of Slocum rotation gauges and a bone scriber.

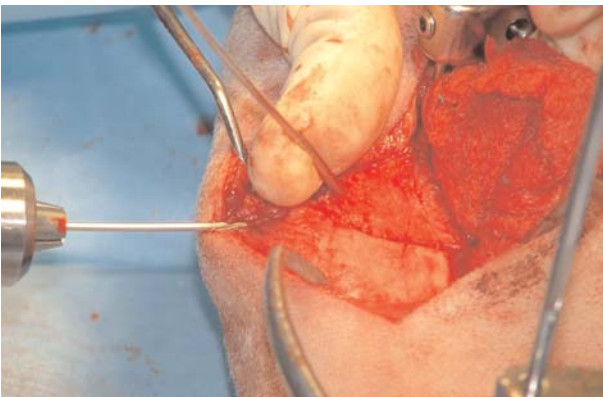


The proximal tibial portion is rotated using pressure on the angled pin until the scored rotation guide lines are aligned.

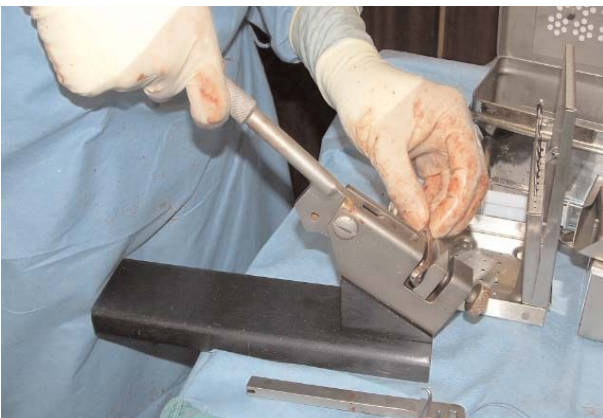



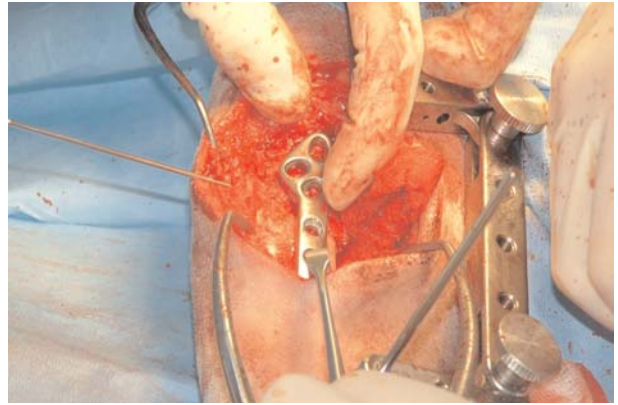
The proximal tibial portion is rotated using pressure on the angled pin until the scored rotation guide lines are aligned.



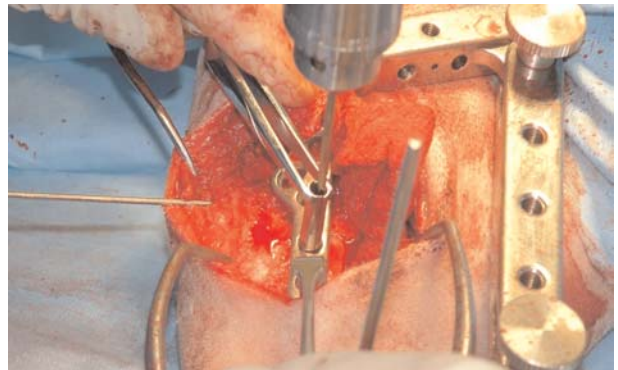
A temporary fixation pin (arthrodesis wire) is drilled when correct rotation has been achieved to stabilise the osteotomy during plating. Starting this pin at the insertion of the patellar ligament and aiming it sagittally, perpendicular to the long axis of the tibia, will ensure adequate temporary stabilisation of the proximal tibia whilst the plate is fixated.



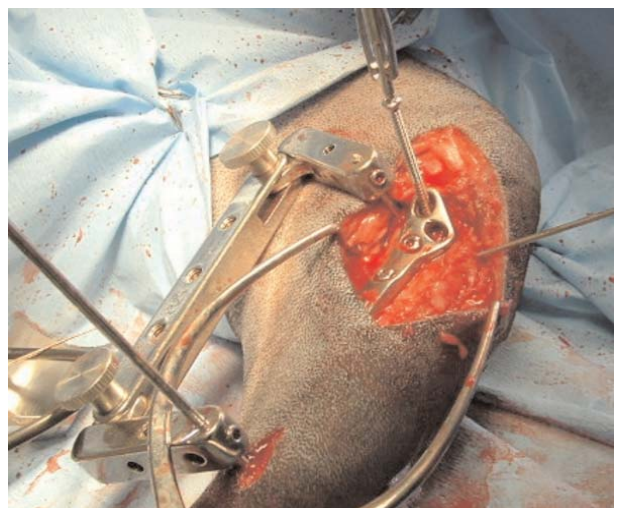A Slocum TPLO plate is contoured using a plate bending press and checked for appropriate alignment. A slight overbend is placed to ensure equal apposition of both cis- and trans- cortices. Proximal torsion of the plate will also be typically required. Alternative plates have recently been marketed, the author currently uses the Vet Instrumentation pre-contoured plate, and contours using the small bone plate press together with plate benders to exert any further torsion required.



Extra plate curvature at the most proximal aspect of the plate may be required, and may deform the screw hole leading to bending of the screw head as it is tightened. If the most proximal aspect of the plate is heavily contoured, then when drilling the pilot screw hole a) ensure that you are aiming at the fibular head. Using the Vet Instrumentation aiming device may facilitate this, and help avoid placing this most proximal screw into the joint, a reported possible complication b) start the pilot hole towards the distal aspect of the screw hole. This will minimise torsion on the screw head when the screw is finally tightened.

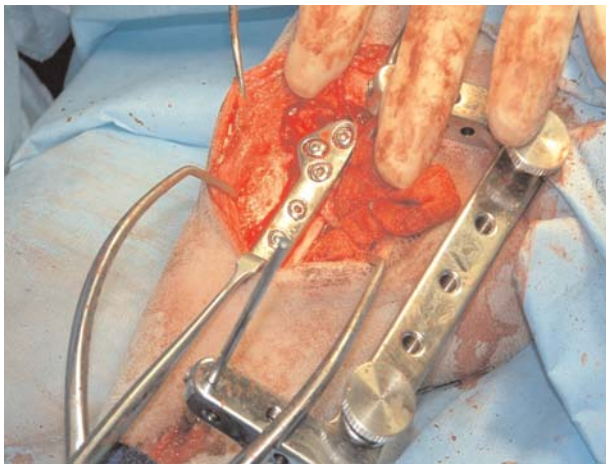


Screws are placed in distal portion first. Use of tissue protection is advised to minimise damage to drill and tap.

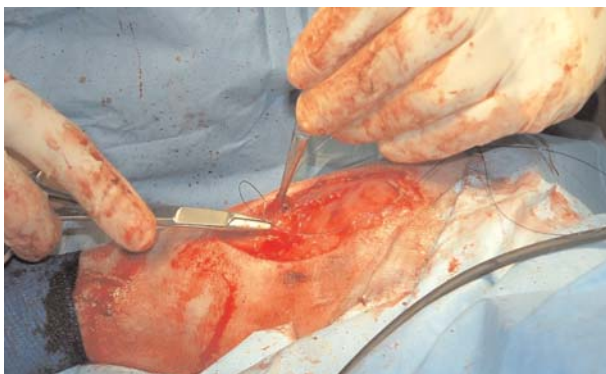


Proximal screws may be placed in compression, and are typically roughly double the length of diaphyseal screws. In giant breeds, screws of length up to 55mm have been required.





TPLO plate in situ. Ensure that the swab protecting the gastrocnemius is withdrawn. The stabilisation jig, if used, is removed at this stage. Do not miss closing the distal jig pin incision.



Closure of periosteum and soft tissue layers is important to protect the plate site. Orthogonal post-op radiographs ensure that implants are correct and tibial plateau angle has been altered appropriately.



Post-operative management following discharge includes Non-Steroidal analgesia, exercise restriction, physiotherapy and hydrotherapy, the latter being routinely encouraged to achieve optimal outcomes. Post-operatively it is difficult to bandage up to and above the stifle bandage slipping is a frequent complication. The author leaves the limb unbandaged, but advises owners that hock oedema post-operatively, typically peaking at day 3 and resolving by day 10. Routine advice includes 7 days strict exercise restriction to toileting only, and controlled lead exercise only up to 6 weeks post-operatively.

## Instrument Check List:

### Power Tools and blades:

A radial cut saw is essential for this procedure as described. Some surgeons are making the radial cut using a small reciprocating saw. This has the benefit of offering a virtually infinite range of radial cuts. Using radial blades the surgeon is restricted to the available blade diameter, currently 18, 21, 24, 27 and 30mm.

TPLOSW	TPLO Saw (Halls hose)
TPLOBHUB	Saw hub only for 18, 24 & 30mm blades
TPLOB18	18mm Stainless Blade
TPLOB24	24mm Stainless Blade
TPLOB30	30mm Stainless Blade
GA200 + GB124R	Aesculap TPLO Saw (Aesculap Hose)
GC544R	18mm Radial Blade
GC545R	20mm Radial Blade
GC546R	24mm Radial Blade
GC547R	30mm Radial Blade

TPMDR15182430	Mandrel for 18,24 & 30mm Titanium Blades
TPMDRL2127	Mandrel for 21 & 27mm Titanium Blades
TPBL18	18mm Titanium Blade
TPBL21	21mm Titanium Blade
TPBL24	24mm Titanium Blade
TPBL27	27mm Titanium Blade
TPBL30	30mm Titanium Blade

### Implants

TPLOS35L	Slocum Style Flat 3.5mm Left
TPLOS35R	Slocum Style Flat 3.5mm Right
TPLOS27L	Slocum Style Flat 2.7 Left
TPLOS27R	Slocum Style Flat 2.7 Right

TPLOS35LPC	Slocum Style Pre-contoured 3.5 Left
TPLOS35RPC	Slocum Style Pre-contoured 3.5 Right

TPLODEL35BL	Delta Style 3.5 Broad Left Pre-contoured
TPLODEL35BR	Delta Style 3.5 Broad Right Pre-contoured
TPLODEL35L	Delta Style 3.5 Left Pre-contoured
TPLODEL35LR	Delta Style 3.5 Right Pre-contoured
TPLODEL27L	Delta Style 2.7 Left Pre-contoured
TPLODEL27R	Delta Style 2.7 Right Pre-contoured

TPLOCAD18L	Cadmus 18mm (2.7) Left
TPLOCAD18R	Cadmus 18mm (2.7) Right
TPLOCAD24L	Cadmus 18mm (3.5) Left
TPLOCAD24R	Cadmus 18mm (3.5) Right
TPLOCAD30L	Cadmus 18mm (3.5) Left
TPLOCAD30R	Cadmus 18mm (3.5) Right

TPLO35LPCL	3.5 Locking plate Left
TPLO35LPCR	3.5 Locking Plate Right

### Hand Instruments:

001492	Slocum Rotation Gauges 5-15mm
TPLOJIG	TPLO Basic Jig
TPLOJIGL	TPLO Standard Jig Large
TPLOJIGS	TPLO Standard Jig Small
TPLO32	Jig pins 3.2mm (1/8")
001112	Stifle Distractor
001113	Small Stifle Distractor
001113VS	Very small joint distractor for mini arthrotomy
06054	Beaver Type Blade Handle
05904	No 64 round end
05905	No 65 Blades (sharp mini no 11) x 25
05906	No 65A Blades (extra small no 11) x 25
001408	Meniscus probe 1mm tip
001409	Meniscus probe 2mm tip
101185	Toothed Halstead Meniscus Clamps

